

Use of the Kishigami Atlantoaxial Tension Band in Eight Toy Breed Dogs with Atlantoaxial Subluxation

ESTEBAN PUJOL, DVM, BERNARD BOUVY, DVM, MS, Diplomate ACVS & ECVS, MIGUEL OMAÑA, DVM, MAR FORTUNY, DVM, LUIS RIERA, DVM, and PEDRO PUJOL, DVM

Objective—To determine the applicability, complications, and long-term functional outcome of the Kishigami Atlantoaxial Tension Band (Kishigami AATB) for management of congenital and traumatic atlantoaxial (AA) instability in toy breed dogs.

Study Design—Case series.

Animals—Toy breed dogs (n = 8) with congenital or traumatic AA instability.

Methods—The AA joint of each dog was surgically stabilized through a dorsal approach using the original or a modified version of the Kishigami AATB. Pre- and postoperative neurologic status, radiographs, and complications were reviewed. Follow-up examination was performed at 1 and 12 months.

Results—Functional improvement occurred in 5 dogs; 1 dog did not improve or worsen and 2 dogs were euthanatized at owner request. Adequate reduction and stabilization was achieved in 7 dogs based on immediate postoperative radiographs; failure of reduction was evident in 1 dog. No relevant complications occurred.

Conclusions—Kishigami AATB may be acceptable as an alternative method for dorsal stabilization of AA subluxation in toy breed dogs in which use of ventral screws or pins is challenging. Experience with this technique in a larger population is necessary to compare our results to those reported by ventral approach.

Clinical Relevance—The surgical technique described is effective, safe, and simple in the surgical treatment of AA subluxation in toy breed dogs.

© Copyright 2010 by The American College of Veterinary Surgeons

INTRODUCTION

INSTABILITY OF the atlantoaxial (AA) joint results from loss of intervertebral ligamentous support often associated with aplasia, hypoplasia, or a dorsal deviation of the dens. AA subluxation is a congenital or developmental disease affecting toy breed dogs whereas traumatic AA subluxation may occur in any breed of dog and at any age. Irrespective of cause, AA instability causes acute or chronic spinal cord compression.^{1,2} The main radiographic sign of AA subluxation is an enlargement of

the space between the tip of the dorsal process of the axis and the dorsal arch of the atlas. Associated clinical signs range from neck pain to tetraplegia and death from respiratory arrest.^{2,3}

Treatment of AA instability remains controversial. Conservative treatment has been reported as an alternative to surgical management in dogs with acute onset of clinical signs and no previous history of neurologic dysfunction, in young dogs with immature bone where surgical fixation may not provide adequate stability, and when financial constraints limit treatment options.^{4,5}

From the Department of Small Animal Surgery, Centre Hospitalier Vétérinaire Frégis, Arcueil, France; and the Small Animal Clinic, “Canis,” Palma de Mallorca, Balearic Islands, Spain.

Presented in part at the 16th Annual Scientific meeting ECVS 2007, Dublin, Ireland.

Corresponding Author: Esteban Pujol, DVM, Department of Small Animal Surgery, Centre Hospitalier Vétérinaire Frégis 43, Avenue Aristide Briand, 94110 Arcueil, France. E-mail: estebanpujol@gmail.com.

Submitted July 2008; Accepted February 2009

© Copyright 2010 by The American College of Veterinary Surgeons

0161-3499/09

doi:10.1111/j.1532-950X.2009.00613.x

Conservative approaches include use of an immobilizing cervicothoracic splint (median, 8.5 weeks) and administration of steroid drugs.⁴ Complications are related directly to splint trauma with corneal ulcers, moist dermatitis, and otitis being most common.⁴

Surgical stabilization of the AA joint is recommended for dogs with severe neurologic dysfunction. Dorsal stabilization techniques include use of orthopedic wire, prosthetic suture, nuchal ligament, Kirschner wires maintained with polymethylmethacrylate, or a metallic retractor.^{3,6–14} Ventral stabilization can be achieved using screws inserted in lag fashion, plates, or Kirschner wires with or without PMMA reinforcement.^{3,12,15–19} Reportedly, the best results are obtained by ventral approach and stabilization of the joint with screws inserted in lag fashion¹⁵; however, this technique is sometimes very challenging in toy breed dogs because of the relative size of available implants and bones, leading to surgical complications, and or failure. Dorsal procedures, particularly the use of orthopedic wire or nonmetallic suture, are problematic because implant passage through the spinal canal of the atlas is associated with a substantial risk of iatrogenic spinal cord damage.^{7–12}

Although the Kishigami Atlantoaxial Tension Band (Kishigami AATB;) was described 25 years ago,⁸ it has only been recently available commercially. The Kishigami AATB reduces the risk of damaging the spinal cord because it rests in the epidural space without crossing the arch of the atlas. To our knowledge, the long-term outcome of AA joint stabilization with the Kishigami AATB has not been reported in dogs. Thus, our purpose was to report our experience with use, complications and long-term outcome of the Kishigami AATB for dorsal stabilization of AA joint in 8 toy breed dogs with wither congenital or traumatic AA instability.

MATERIALS AND METHODS

Inclusion Criteria

Medical records (1998–2006) of toy breed dogs that had dorsal surgical stabilization of the AA joint with the Kishigami AATB were reviewed. No other stabilization method was used during this period. Dogs that had been stabilized with the Kishigami AATB were included if they had confirmed preoperative radiographic diagnosis of AA subluxation and quality images of dens morphology, postoperative radiographs documenting AA joint reduction, and 4 week and 1 year neurologic follow-up examination. Information obtained from the medical records included: breed, age, sex, body weight at surgery, cause of the instability, structure of the dens, and time from clinical onset to admission.

The neurologic status of each dog was graded¹²: tetraplegia (grade 1), nonambulatory paresis (grade 2), ambulatory paresis (grade 3), ataxia or spasticity (grade 4), and normal gait

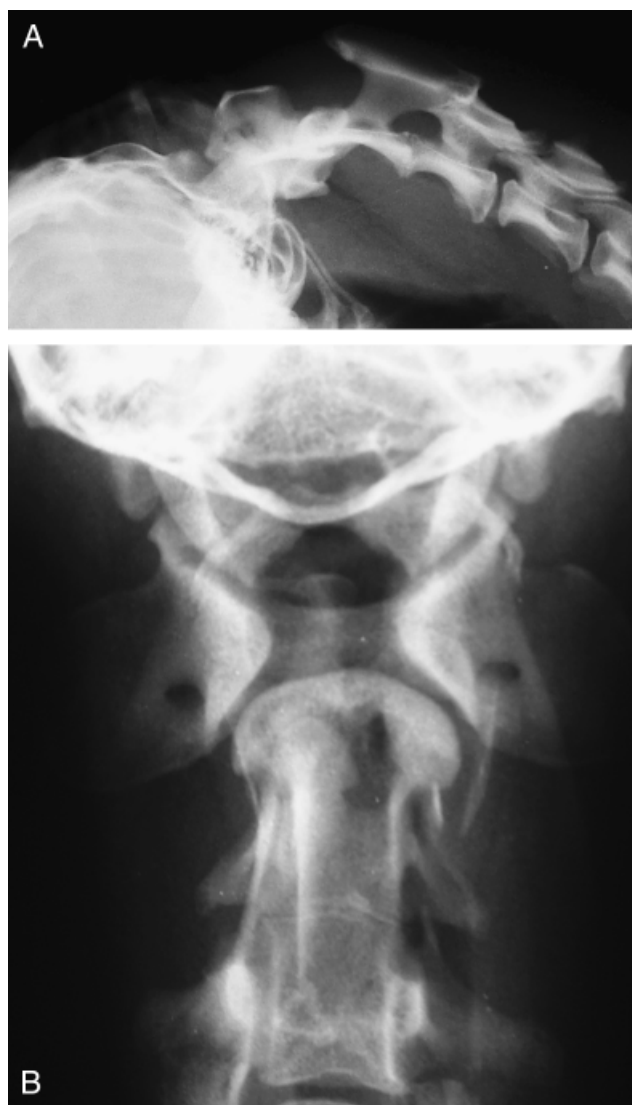

Fig 1. Dog 8. Preoperative radiographs. (A) Lateral cervical projection showing fusion of C2–C3 and atlantoaxial subluxation: the space between the dorsal lamina of the atlas and the spinous process of the axis is clearly enlarged. (B) Dorsoventral cervical projection showing agenesis of the dens and nonunion of the ventral arch of the atlas.

(grade 5). Diagnosis of AA subluxation was based on examination of lateral and dorsoventral cranial cervical spinal radiographs and was confirmed at surgery by verification of the space between the tip of the spinous process of the axis and the dorsal arch of the atlas (Fig 1).

Two retractors were used: a Kishigami AATB custom made according to the original description⁸ (Fig 2) and a modified Kishigami AATB designed without the center leg (Insorvet, Barcelona, Spain; Fig 3). We used 3 different sized Kishigami AATB (small [S], medium [M], and large [L]) depending on vertebral dimensions measured on a lateral radiographic projection.

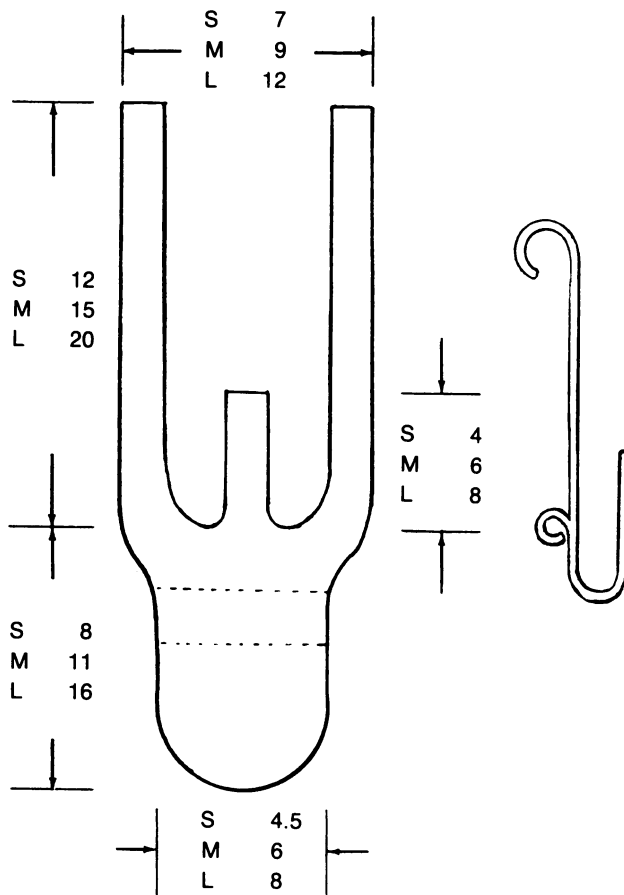


Fig 2. Design of the original Kishigami Atlantoaxial Tension Band (from Kishigami⁸), numbers correspond to millimeters. The central hook of the original device is shown.

Surgical Technique

The same surgeon performed all surgical procedures. Dogs were positioned in ventral recumbency with towels placed between the surgical table and the neck to slightly elevate the cervical vertebral column. After aseptic preparation, the AA joint was exposed by a dorsal approach; the epaxial musculature was periosteally elevated from the dorsal lamina of the atlas and from the dorsal process, lamina, and pedicles of the axis. Stability between the atlas and axis was evaluated. Two (original Kishigami AATB) or 3 small holes (modified Kishigami AATB) were drilled in the dorsal process of the

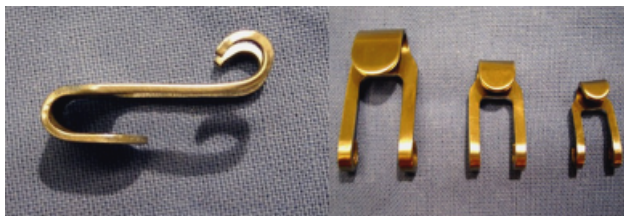


Fig 3. Lateral and ventral views of three sizes of modified Kishigami Atlantoaxial Tension Band (without the center leg).

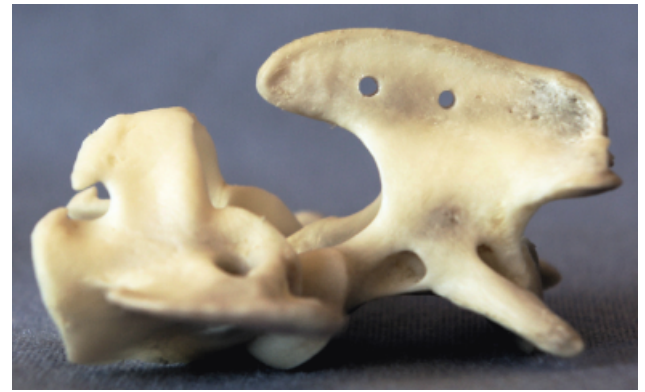


Fig 4. Atlantoaxial joint specimens: 2 holes are drilled in the spinous process of the axis.

axis (Fig 4). Malleable stainless steel wire (0.6–0.8 mm) was threaded through the caudal hole of the axis and both ends were directed through the next hole intersecting each other (Fig 5). The dorsal atlantooccipital fascia cranial to the arch of the atlas was then carefully incised to a width equal to the cranial hook of the Kishigami AATB, which was carefully inserted over the dorsal arch of the atlas in the epidural space (Fig 6). This was the most delicate step.

If the original device was used, a supplementary nonabsorbable polyester suture (2-0 Miralene[®], Braun Medical,

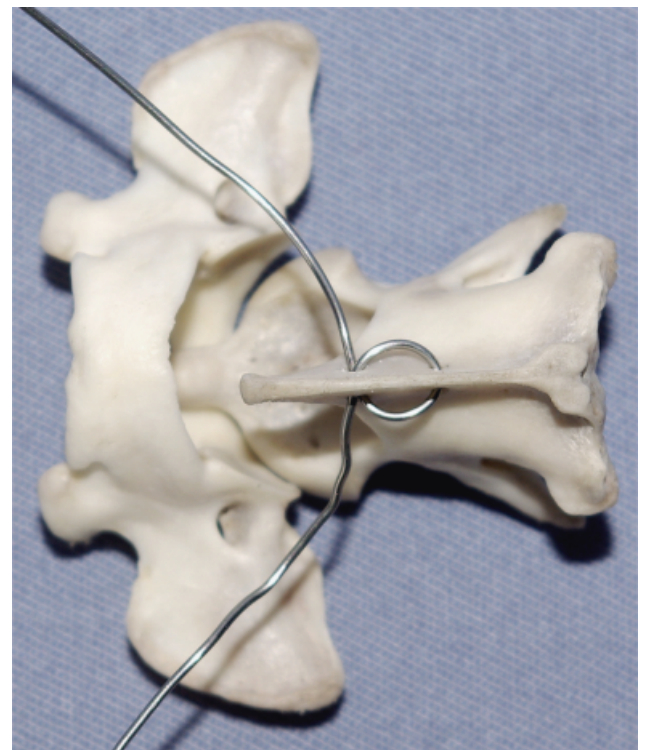


Fig 5. Stainless steel wire (0.6mm) is threaded through the caudal hole of the axis, both ends are then bent forward along the dorsal spine and directed through the next hole intersecting each other.

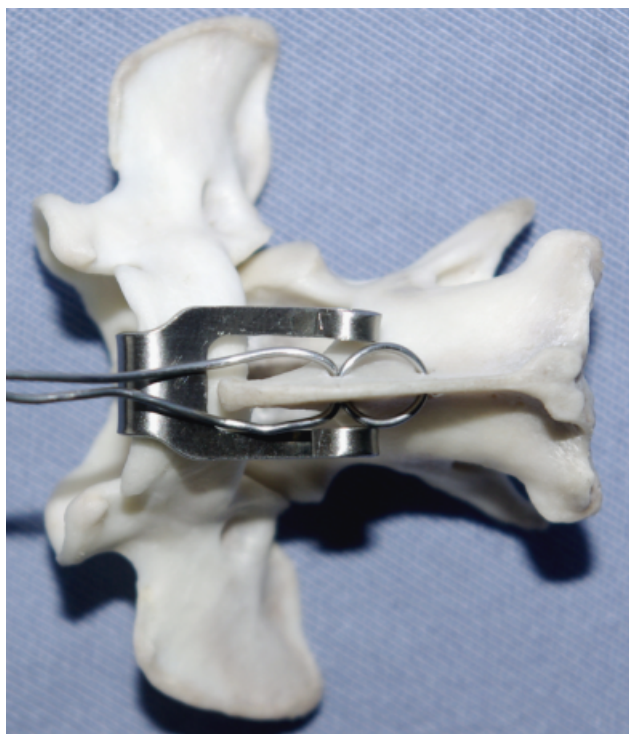

Fig 6. The cranial hook of the Kishigami Atlantoaxial Tension Band is inserted over the dorsal arch of the atlas.

Barcelona, Spain) was applied between the center ring of the Kishigami AATB and the cranial hole of the axis. This suture was slowly tensioned so the AA joint was brought into normal position (this step was omitted with the modified Kishigami AATB). The surgeon pushed down the spinal process of the axis to reduce the joint in each dog and when the spinal process of the axis was lying over and in contact with the atlas, the joint was assumed to be properly reduced. At this time the Kishigami AATB was not stable. Some laxity remained in the dorsoventral plane so the retractor could be moved slightly, which allowed to the ends of the wire be threaded outward

through the hooks of the side legs of the Kishigami AATB and bent backward. Vertebral alignment and position were checked and any persisting flexion was reduced by adjusting the length of the wire. Excess ends of the wire were cut and hooks of the legs were crushed to ensure stable reduction (Fig 7). Muscles, subcutaneous tissue, and skin were closed in layers. The surgical technique was identical in all dogs with the exception of the device used.

Postoperative lateral and dorsoventral radiographic projections were obtained to verify anatomic reduction and correct placement of the Kishigami AATB (Fig 8). A soft neck brace and cage rest were recommended for 2 weeks. Morphine chlorhydrate (0.1 mg/kg) was administered for 24 hours after surgery, then meloxicam (0.2 mg/kg) once daily for 7 days.

All dogs were evaluated by the same surgeon at ~ 4 weeks and 12 months. Neurologic grade was established with excellent outcome defined as a final neurologic grade of 5, good outcome as grade 4, and poor outcome as grade 3 or less. A successful functional outcome was defined as improvement in clinical signs without signs of recurrence.

RESULTS

Eight dogs (mean weight, 2.6 kg; range 0.8–5 kg; mean age 21.8 months; range 7–60 months) representing 3 toy breeds and crossbreeds were included (Table 1). Mean time from onset of clinical signs to admission was 38.3 days (range, 3–120 days). In 2 dogs, clinical signs occurred acutely after trauma whereas signs occurred spontaneously in 6 dogs and were attributed to congenital instability. Radiographically, the dens was hypoplastic (2 dogs), aplastic (3), or normal (3, including 2 traumatic injuries); none of the dogs had dorsal deviation of the dens. Surgical evaluation of the AA joint confirmed the radiographic diagnosis of AA subluxation. At admission, 3 dogs had a neurologic grade of 2, 4 dogs had grade 3, and 1 dog was grade 4 (Table 1); none of the dogs was tetraplegic.

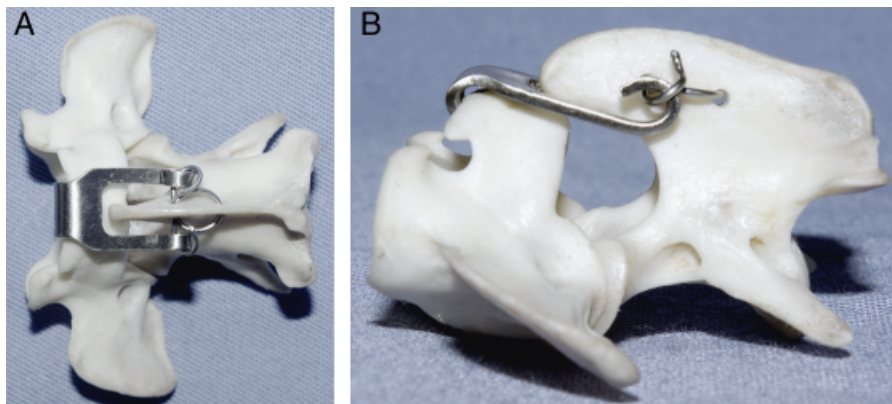


Fig 7. (A) Dorsal and (B) lateral views of a specimen showing positioning of the Kishigami Atlantoaxial Tension Band (Kishigami AATB). The 2 ends of the wire are brought forward, threaded outward through the hooks of the side legs of the Kishigami AATB, and bent backward, excess ends of wire are cut, then crushed.

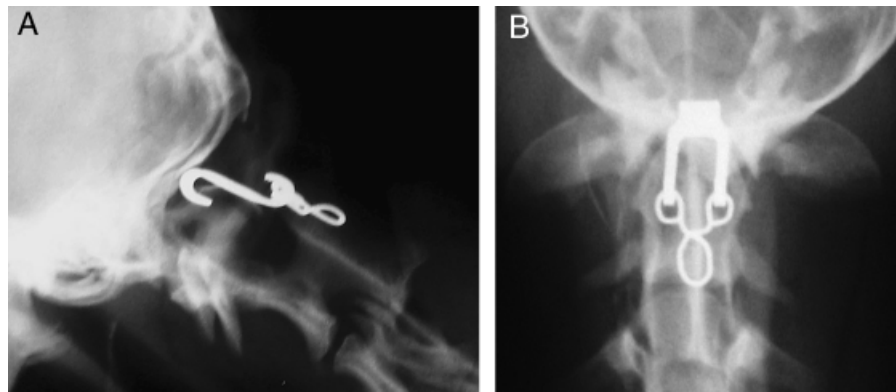


Fig 8. Dog 6. (A) Lateral and (B) dorsoventral projections of the atlantoaxial joint showing a good reduction and alignment of the atlas and axis.

Four dogs received the original Kishigami AATB and 4 dogs had a modified Kishigami AATB. No intraoperative complications occurred and no technical differences in device application were appreciated. Postoperative radiographs showed anatomic AA alignment except in dog 7 that had failure of reduction (Figs 9 and 10); reduction of C2 to its correct ventral location was not achieved.

Outcome

All dogs were discharged within 72 hours of surgery and none had short-term complications related to surgery. Neurologic examination at 4 weeks revealed a successful functional outcome in 5 dogs (Table 1). Maximal neurologic status was observed within the 1st 4 weeks after surgery in 6 dogs. Within the 1st postoperative month dogs 1 and 5 were euthanatized at owner request because of lack of improvement (dog 1) or deterioration (dog 5) of clinical signs. There was no radiographic evidence suggesting neurologic dysfunction was related to the implants or other visible abnormalities in these dogs. At 12 months, 2 dogs had an excellent outcome (grade 5) having improved by 3 grades and 4 dogs had a good

outcome (grade 4), having improved 1 grade (3 dogs) or remained unchanged (1 dog).

DISCUSSION

If one considers functional success of AA subluxation treatment as improvement of neurologic status with no signs of recurrence, this was effectively attained in 5 dogs. One dog that had degradation of neurologic status after surgery and 1 dog that did not improve were euthanatized within the 1st month after surgery.

If one considers the surgical goals for correction of AA subluxation as decompression of the spinal cord and anatomic reduction and stabilization of the AA joint without directly causing acute morbidity and mortality,^{20,21} these objectives were obtained in all but 1 dog. Failure of reduction during surgery occurred in dog 7 without deleterious functional consequences and there was no progression of neurologic signs during the 12-month follow-up. In our opinion, a dorsal approach is simpler and safer than a ventral approach. The neurovascular risks of the conventional ventral approach have motivated the development of a parasagittal approach²²; however, these

Table 1. Summary Data for 8 Dogs with Atlantooccipital Malformation

Dog	Breed	Age (Months)	Sex	Weight (kg)	Cause	Malformation	Onset to Admission (Days)	Neurologic Status ¹²			Retractor
								Preoperative	4 Weeks	12 Months	
1	Yorkshire	9	M	1.5	Congenital	Agnesia of the dens	44	2	2	NA	Original
2	Yorkshire	12	F	2	Congenital	Hypoplasia of the dens	24	2	5	5	Original
3	Cross breed	18	F	3	Congenital	Hypoplasia of the dens	120	3	4	4	Original
4	Cross breed	36	M	4	Traumatic	Normal dens	3	3	4	4	Original
5	Pomeranian	9	M	5	Congenital	Normal dens	63	3	2	NA	Modified
6	Chihuahua	7	F	0.8	Congenital	Agnesia of the dens	10	3	4	4	Modified
7	Yorkshire	60	M	4	Traumatic	Normal dens	12	4	4	4	Modified
8	Cross breed	24	M	2	Congenital	Agnesia of the dens	30	2	5	5	Modified

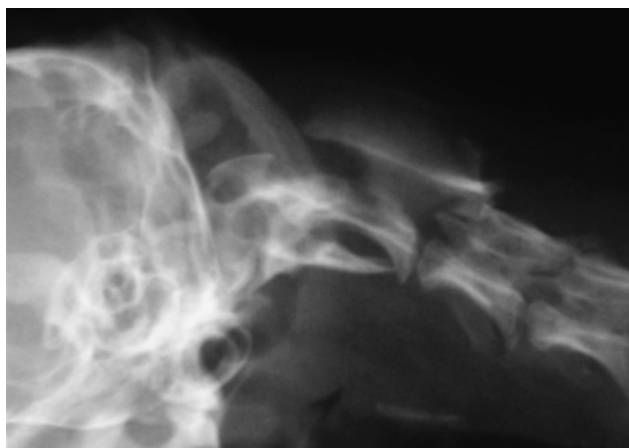


Fig 9. Dog 7. Preoperative radiograph showing severe atlantoaxial subluxation.

concerns are irrelevant for dorsal median approach required for AA stabilization with Kishigami AATB.

Evaluation of the use of the Kishigami AATB was one of our objectives. Application of this device has been considered easy and safe in all cases comparing this technique with the experience of the authors with other dorsal or ventral procedures. We think that the risk of damaging the spinal cord with this procedure is reduced compared with other dorsal techniques that require pulling wires or sutures through the spinal canal of the atlas. The most delicate step is positioning the cranial hook of the Kishigami AATB into the epidural space at the level of the dorsal atlantooccipital fascia.

We did not appreciate differences between the 2 types of Kishigami AATB. Dogs 2–4 improved with the orig-

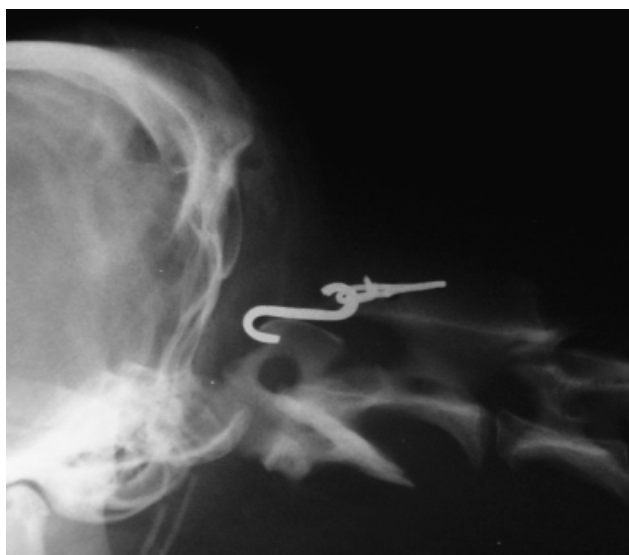

Fig 10. Dog 7. Postoperative radiograph showing failure of reduction of the atlantoaxial joint.

inal device and dogs 6 and 8 improved with the modified version without the center ring. Dog 7 did not improve or worsen with the modified version. The center ring of the original design permits use of an additional suture in the dorsal process of the axis, to bring the AA joint into a normal position for a better reduction of the AA luxation before definitive placement of the wire. We were concerned that making 3 holes in the dorsal process of the axis in toy breed dogs could weaken the bone leading to more complications, which is why we chose to use the modified version after the 4th dog. Dogs operated after completion of this study have all been treated with the modified Kishigami AATB.

We used a soft neck brace (cotton) because of the high rate of complications with reported with a cervicothoracic splint.⁴ None of our dogs had complications related to the brace. Further, no clinically important complications were recognized with the surgical procedure. One suggested complication with other techniques is intraoperative caudal brainstem trauma causing respiratory abnormalities and cardiac arrest.^{12,19} This complication is unlikely with Kishigami AATB because it rests over the dorsal arch of the atlas and the cranial hook is positioned in the epidural space without the necessity of pulling wire or sutures through the spinal canal. Failure of the implant is a reported complication of other means of dorsal stabilization. Often the dorsal lamina of the atlas is reported to be very thin and this contributes to failure.^{11,13} The cranial hook of the Kishigami AATB is wider than a wire suture, which increases the surface of contact between the implant and the bone, leading to a better repartition of forces and consequently to less implant failure. Insufficient tightening of the wire may lead to Kishigami AATB instability and de novo subluxation of the AA joint. Such complications were not clinically observed in our dogs. The only technical drawback was the failure of reduction of the AA joint in dog 7, but this dog was ambulatory after surgery.

Our clinical results suggest that Kishigami fixation is stable and durable for at least 1 year. Further biomechanical or longer term clinical studies should be performed to confirm this observation and also to assess longer term outcome. Ventral surgical techniques rely on permanent fusion or arthrodesis for long-term stabilization of the AA joint, whereas dorsal procedures depend on fibrous scar formation. We assume that stabilization of the joint by fibrous tissue is sufficient for securing the joint in toy breed dogs over the long term. To our knowledge, a biomechanical study evaluating the effect of AA fusion over the rest of the vertebral column has not been reported. One might postulate that Kishigami stabilization preserves normal physiology of AA motion (i.e., in rotation) and carries less risk of a so-called domino effect than does ventral rigid arthrodesis.

Three dogs did not improve. Dog 7 had failure of joint reduction because reduction of C2 to its correct ventral location was not achieved, suggesting that there can be problems getting C2 to remain in its correct ventral position by dorsal approach. This is likely to have occurred because dogs with chronic AA instability often have a lot of proliferative soft tissue ventrally between C2 and C1 that would be removed to achieve reduction with a ventral approach. This problem could also occur because of excessive wire tightening. It also demonstrates that reduction of C2 into its correct ventral position cannot always be achieved with our technique. This dog remained stable after surgery with only an ataxic gait. The consequences of failure of reduction are unknown but over reduction seems to be less damaging for the spinal cord than under reduction. This theory is supported by the position of the dens of the axis where with under reduction the dens could compress the spinal cord ventrally.

The reason dogs 1 and 5 did not improve is unknown. Residual or continued neurologic deficits result from progressive demyelination, axonal degeneration, or malacia because of continued AA instability or other concomitant neurologic disease.⁴ Any of these events may have contributed to failure of improvement in dogs 1 and 5; unfortunately necropsy was not performed. Radiographs taken before euthanasia did not show any implant related cause. Advanced imaging (CT, MRI) could provide more information about the failure of improvement and could also be useful for surgical planning. Such imaging techniques could facilitate identification of other structures (soft tissues or bone) that might compress spinal parenchyma; however, these imaging techniques were not available to us during this study period.

It is difficult to make a truly reliable comparison between our technique and others because of the small number of dogs and the variability in neurologic status within each published case series. Based on our definition of functional success (improvement of neurologic status with no signs of recurrence) our technique was successful in 5 (62.5%) dogs; however, dog 7 that was only mildly affected preoperatively did not improve but remained stable neurologically. If we considered dog 7 as a favorable outcome, our overall success rate would be 75% (6 dogs), comparable to 76% (87/114) success rate collectively in others reports where a ventral approach^{1,2,17-19} was used. No relevant surgical complications occurred during or after the procedure, so if we consider failure of the reduction of dog 7 as a complication, the overall complication rate was 12.5% and our technique compares favorably with the 36.8% (42/114) overall complication rate collectively reported in other ventral technique studies.^{1,2,17-19}

Age at onset of clinical signs (<24 months) has been reported as a positive predictive factor for successful

outcome with AA subluxation stabilization.¹ Six dogs were <24 months old. Two dogs >24 months old also improved. All dogs had clinical signs for <10 months, which has been reported as a positive predictive factor for successful outcome.¹ Conversely, severity of clinical signs has been included as a negative predictive factor for final successful outcome.¹ That is in contrast with our results in 2 dogs that had severe clinical signs (grade 2) before surgery and improved to grade 5 after surgery, demonstrating that it is possible to have cases with poor prognostic indicators that do well.

None of our dogs had dorsal deviation of the dens, which is a contraindication for dorsal stabilization of the joint. If a partial or complete odontectomy is necessary, it can only be performed from a ventral approach. Anatomy of the dens (aplasia in 3 dogs, hypoplasia in 2, and normal in 3) did not appear to influence outcome. Radiographic appearance of the dens of dogs with AA instability has not been of predictive value for a positive outcome,¹ a finding we corroborated.

Study Limitations

Limitations of this study included the low number of cases and its retrospective design. Other limitations were the lack of advanced imaging for dogs that did not improve; follow-up evaluation of dogs by the same surgeon although the neurologic grading system defines distinct grades with little room for subjectivity. The lack of radiographic follow-up with long-term follow-up based only on clinical signs although the 6 surviving dogs have not had recurrence of neurologic dysfunction within 1 year of surgery, implying long-term joint stability.

We found that surgical management of AA instability by use of the Kishigami AATB was simple, safe, and associated with a good or excellent long-term outcome in 6 of 8 dogs. Our results suggest that dorsal placement of a Kishigami AATB is a good alternative method for stabilization of AA instability in dogs. In our opinion, this method seems even more attractive in toy breed dogs (<2 kg) where placement of screws or pins by a ventral approach is very challenging, difficult to reproduce, and has a risk of vertebral fracture because of bone softness. A larger population in a prospective study would provide more reliable information to ascertain the use of the Kishigami AATB for stabilization of AA luxation in dogs.

ACKNOWLEDGMENTS

We thank Mr. Pedro Luna for the original Kishigami AATB manufacture, Dr. Leperlier for photographic expertise, Dr. Moissonnier for technical support, and Drs. Uriarte and Cauzinille for manuscript review.

REFERENCES

1. Beaver DP, Ellison GW, Lewis DD, et al: Risk factors affecting the outcome of surgery for atlantoaxial subluxation in dogs: 46 cases (1978–1998). *J Am Vet Med Assoc* 216:1104–1109, 2000
2. McCarthy RJ, Lewis DD, Hosgood G: Atlantoaxial subluxation in dogs. *Compend Contin Educ Pract Vet* 17: 215–227, 1995
3. Denny HR, Gibbs C, Waterman A: Atlantoaxial subluxation in the dog: a review of thirty cases and an evaluation of treatment by lag screw fixation. *J Small Anim Pract* 29:37–47, 1988
4. Havig ME, Cornell KK, Hawthorne JC, et al: Evaluation of nonsurgical treatment of atlantoaxial subluxation in dogs: 19 cases (1992–2001). *J Am Vet Med Assoc* 227: 257–262, 2005
5. Gilmore DR: Nonsurgical management of four cases of atlantoaxial subluxation in the dog. *J Am Anim Hosp Assoc* 20:93–96, 1984
6. Geary JC, Oliver JE, Hoerlein BF: Atlantoaxial subluxation in the canine. *J Small Anim Pract* 8:577–582, 1967
7. Chambers JN, Betts CW, Oliver JE: The use of nonmetallic suture material for stabilization of atlantoaxial subluxation. *J Am Anim Hosp Assoc* 13:602–604, 1977
8. Kishigami M: Application of an atlantoaxial retractor for atlantoaxial subluxation in the cat and dog. *J Am Anim Hosp Assoc* 20:413–419, 1984
9. LeCouteur RA, McKeown D, Johnson J, et al: Stabilization of atlantoaxial subluxation in the dog, using the nuchal ligament. *J Am Vet Med Assoc* 177:1011–1017, 1980
10. Johnson SG, Hulse DA: Odontoid dysplasia with atlantoaxial instability in a dog. *J Am Anim Hosp Assoc* 25:400–404, 1989
11. Renegar WR, Stoll SG: The use of methylmethacrylate bone cement in the repair of atlantoaxial subluxation stabilization failures—case report and discussion. *J Am Anim Hosp Assoc* 15:313–318, 1979
12. Thomas WB, Sorjonen DC, Simpson ST: Surgical management of atlantoaxial subluxation in 23 dogs. *Vet Surg* 20: 409–412, 1991
13. Van Ee RT, Pechman R, Van Ee RM: Failure of the atlantoaxial tension band in two dogs. *J Am Anim Hosp Assoc* 25:707–712, 1989
14. Jeffery ND: Dorsal cross pinning of the atlantoaxial joint: new surgical technique for atlantoaxial subluxation. *J Small Anim Pract* 37:26–29, 1996
15. Sorjonen DC, Shires PK: Atlantoaxial instability: a ventral surgical technique for decompression, fixation, and fusion. *Vet Surg* 10:22–29, 1981
16. Blass CE, Waldron DR, Van Ee RT: Cervical stabilization in three dogs using Steinmann pins and methylmethacrylate. *J Am Anim Hosp Assoc* 24:61–68, 1988
17. Schulz KS, Waldron DR, Fahie M: Application of ventral pins and polymethylmethacrylate for the management of atlantoaxial instability: results in nine dogs. *Vet Surg* 26:317–325, 1997
18. Sanders SG, Bagley RS, Silver GM, et al: Outcomes and complications associated with ventral screws, pins, and polymethyl methacrylate for atlantoaxial instability in 12 dogs. *J Am Anim Hosp Assoc* 40:204–210, 2004
19. Platt SR, Chambers JN, Cross A: A modified ventral fixation for surgical management of atlantoaxial subluxation in 19 dogs. *Vet Surg* 33:349–354, 2004
20. Cook JR, Oliver JE: Atlantoaxial luxation in the dog. *Compend Contin Educ Pract Vet* 3:242–250, 1981
21. Gage ED, Smallwood JE: Surgical repair of atlantoaxial subluxation in a dog. *Vet Med Small Anim Clin* 65:583–592, 1970
22. Shores A: TL: a modified ventral approach to the atlantoaxial junction in the dog. *Vet Surg* 36:765–770, 2007